



Deutsche
Gesellschaft
für Nuklearmedizin
e.V.



Translational Research in Molecular Imaging and Radionuclid Therapy

September 4 – 6, 2014

Overview Molecular Imaging PET and SPECT

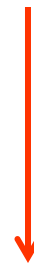**UNIKLINIK
RWTHAACHEN**
KLINIK FÜR NUKLEARMEDIZIN
F.M. Mottaghy

Medical imaging and the pathology cascade

Molecular/Cellular
disturbance



Alterations in
physiology



Structural
lesion

Diagnostic approach

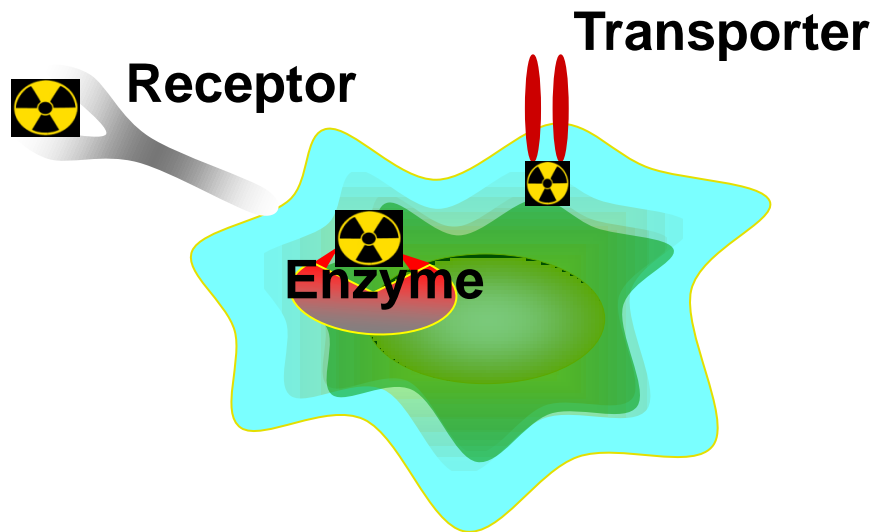
Nuclear/Molecular
Medicine

Radiology



Molecular interactions of radiolabeled probes

In vivo imaging of biological processes with radiolabeled molecular probes

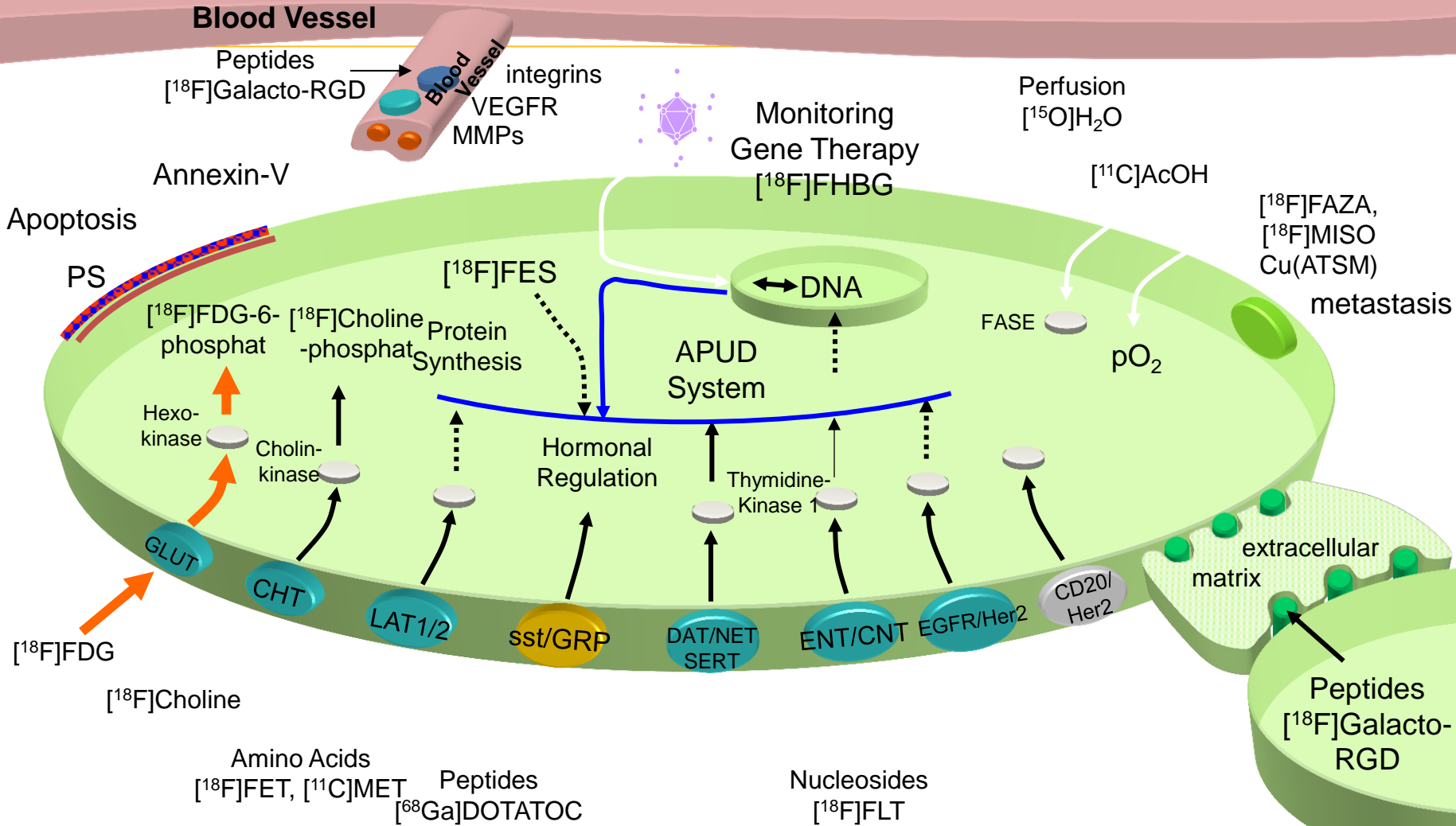


Mechanism of localization

Visualization of overexpression or increased activity of:

- Receptors
- Enzymes
- Transporters

Molecular Probes (Tracers)



Wester et al., Clin Cancer Res 2007



Steps to molecular image acquisition

1. Radionuclide



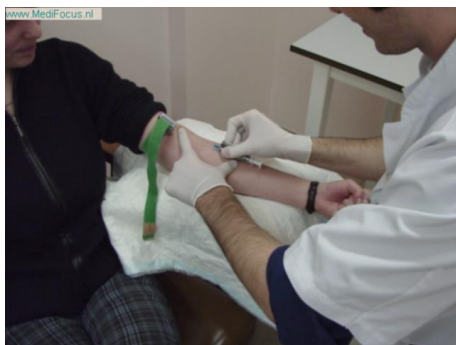2. Synthesis of radiopharmaceutical



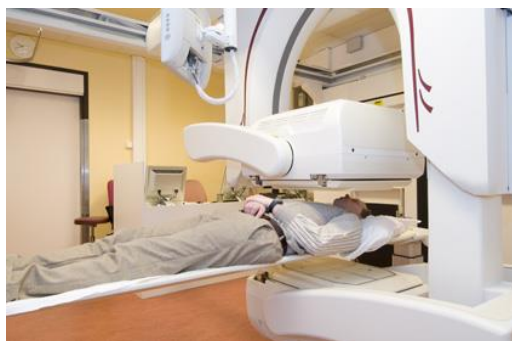3. Radiopharmaceutical



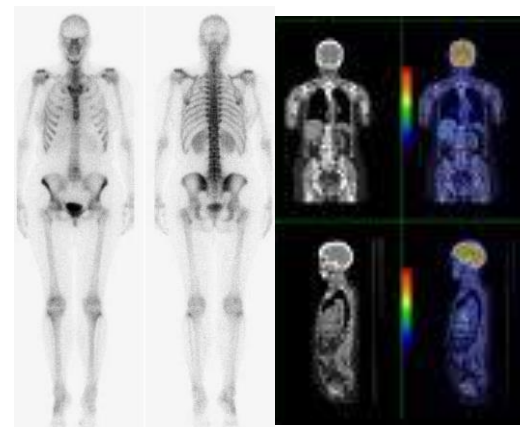
4. Application



5. Scan



6. Image



Planar Scintigraphy

^{99m}Tc

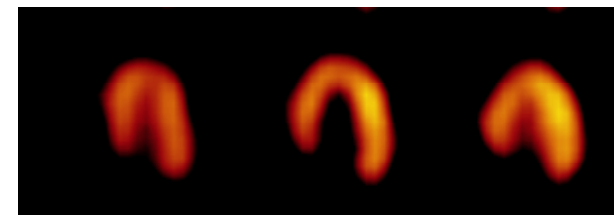
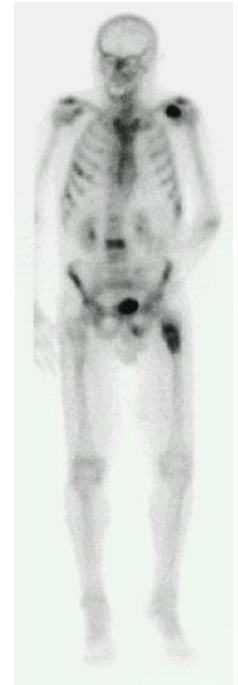
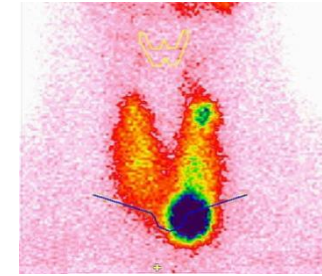
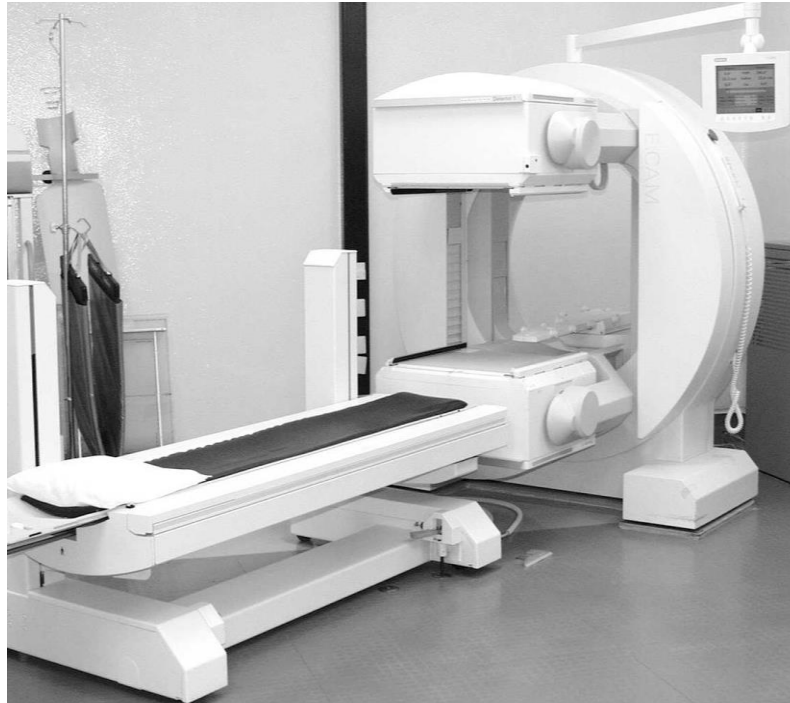6h HWZ
140 keV

Nuklid

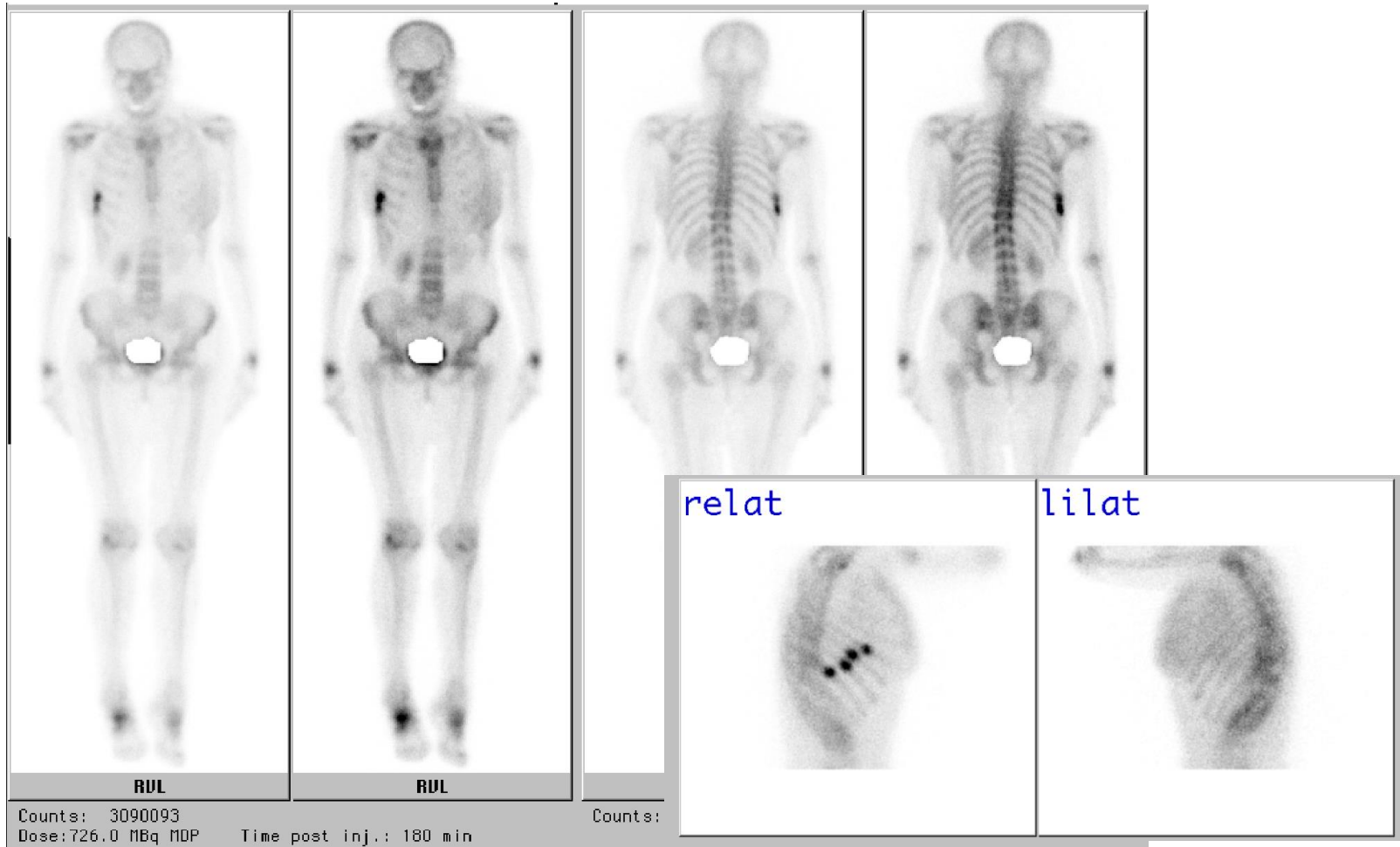


target-
specific

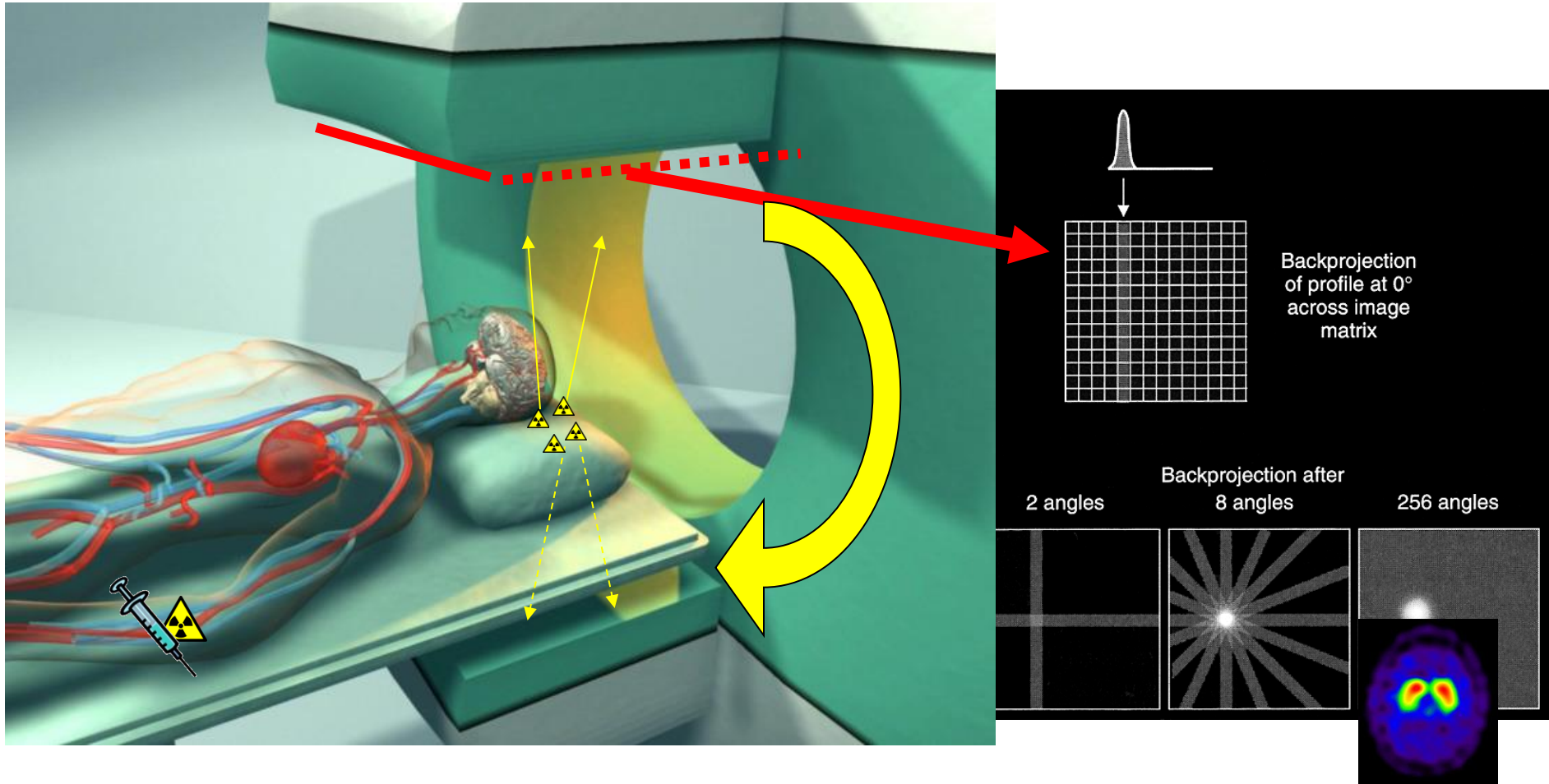
radiopharmaceuticals



Bone-Scintigraphy (^{99m}Tc -MDP)

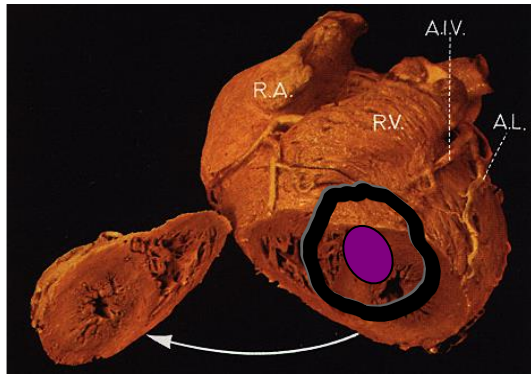


Single Photon Emission Computed Tomography (SPECT)



Myocardial SPECT

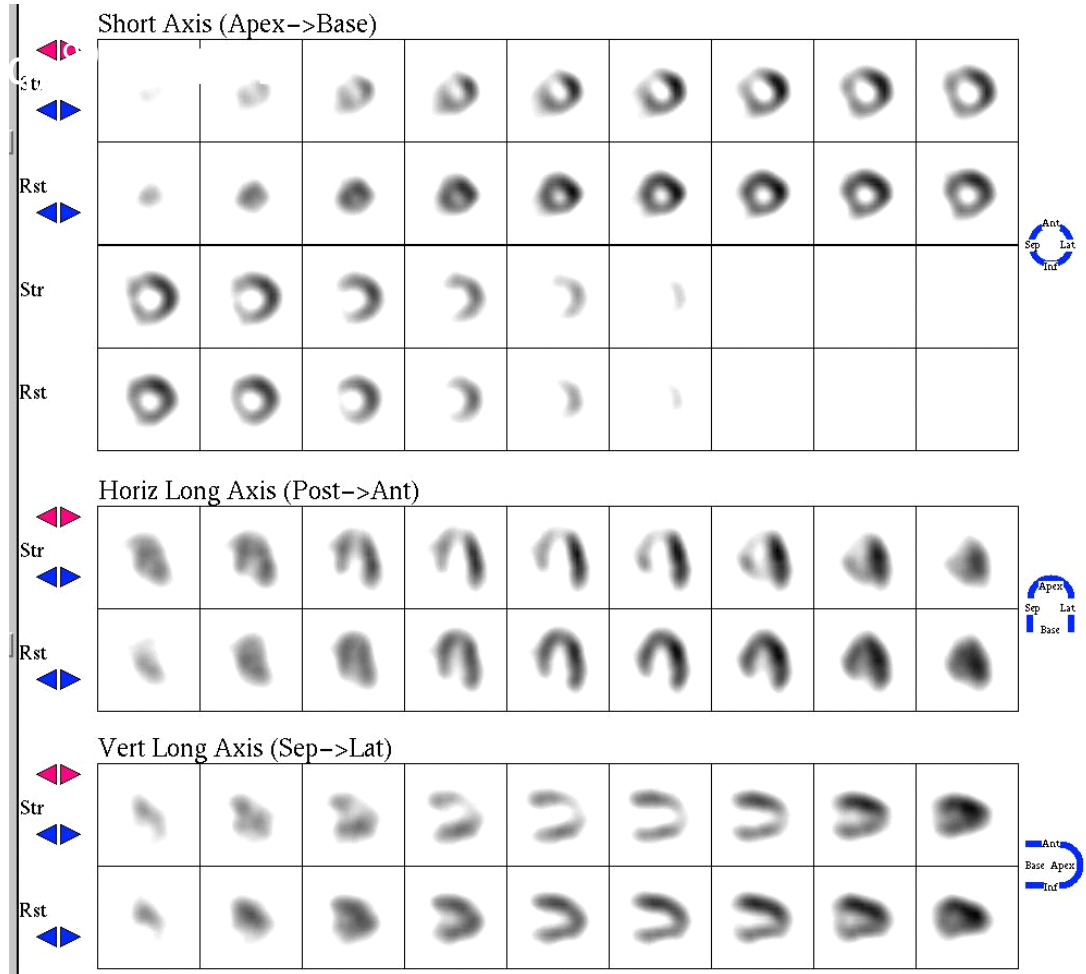
Cardiovascular disease, ergometry until 75 Watt



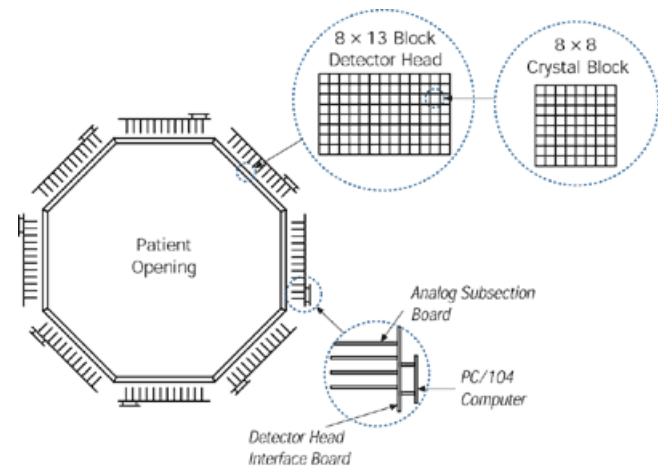
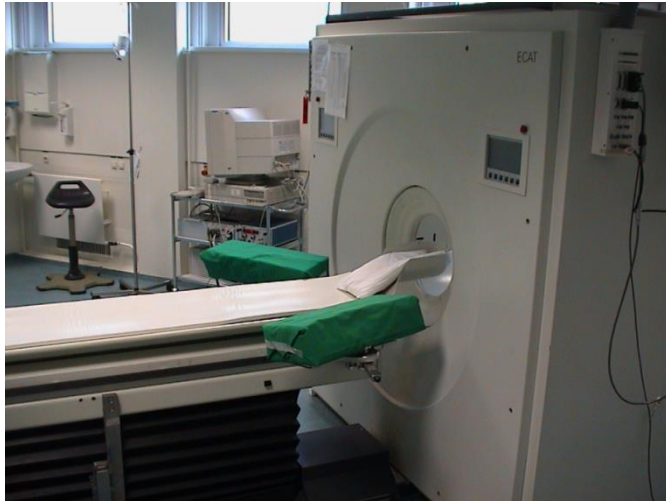
short
axis

horiz.
long
axis

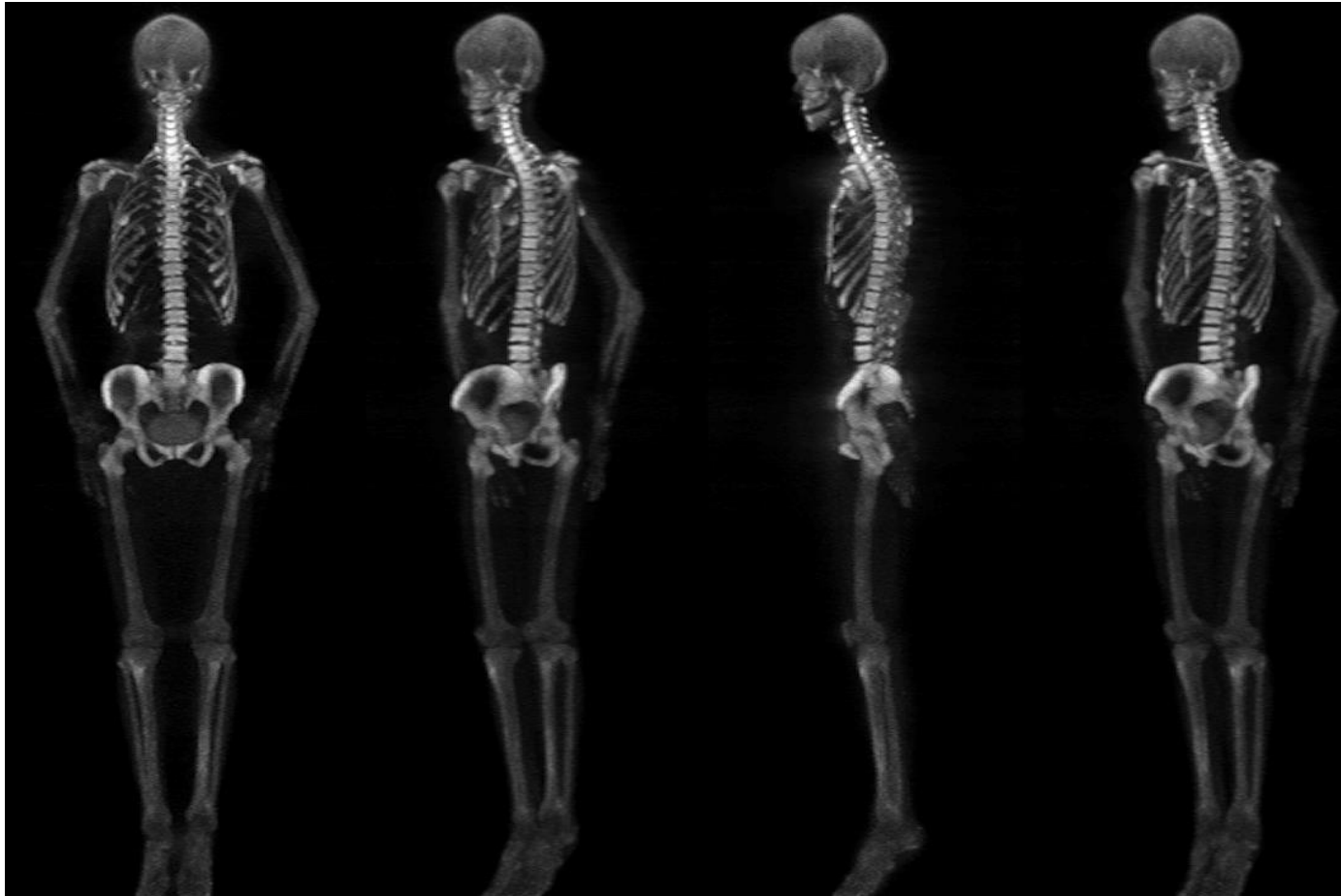vert.
long
axis



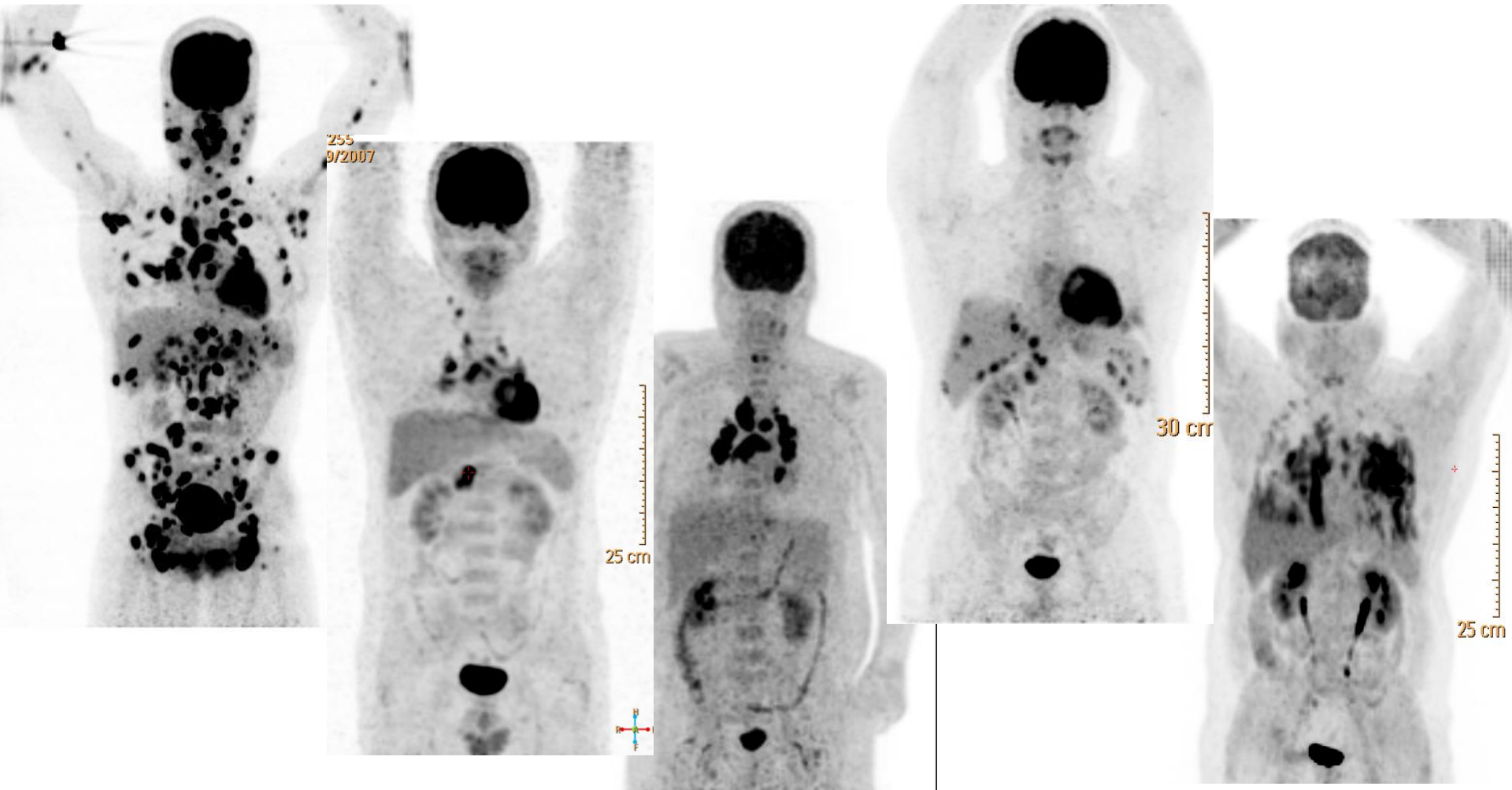
Positronen-Emissions-Tomographie (PET)


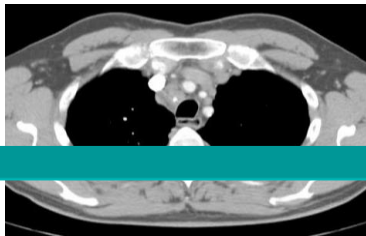



^{18}F -Fluoride PET

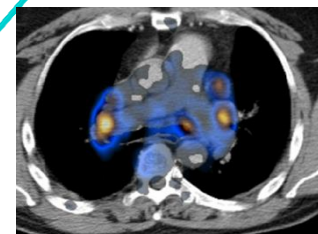


Fluorodeoxyglucose-PET (Sarkoidosis)

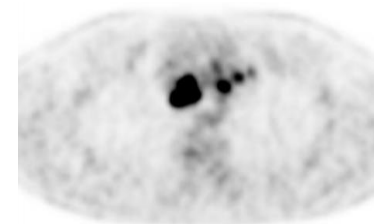




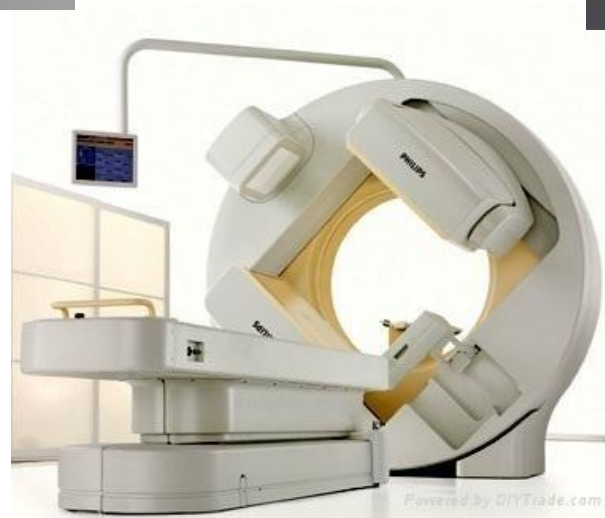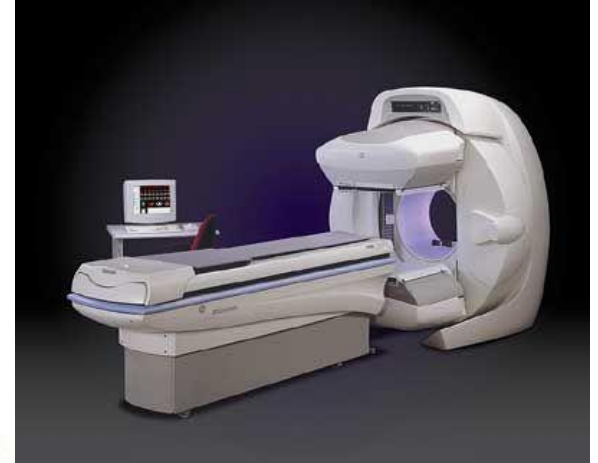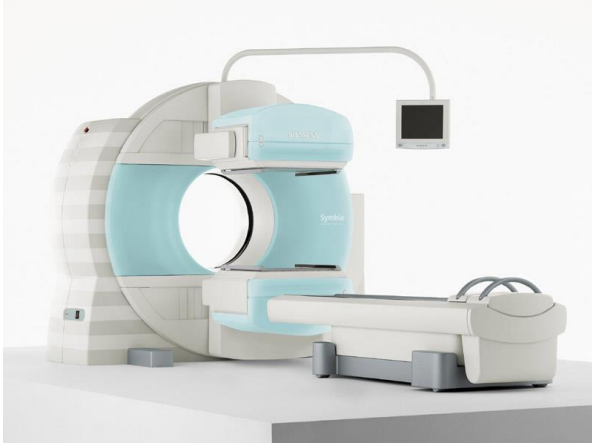
**Multimodal
molecular/functional
Imaging**



CT

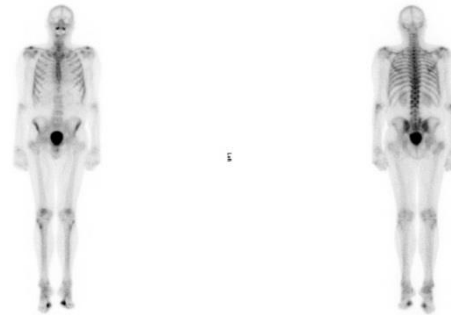

SPECT/CT



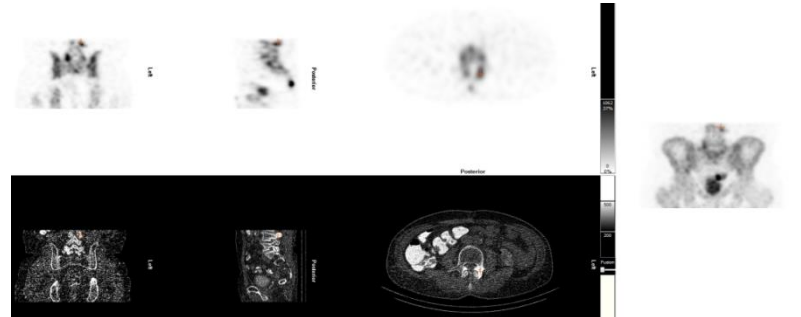
SPECT/CT Prostate Cancer Bone Scan

Staging I

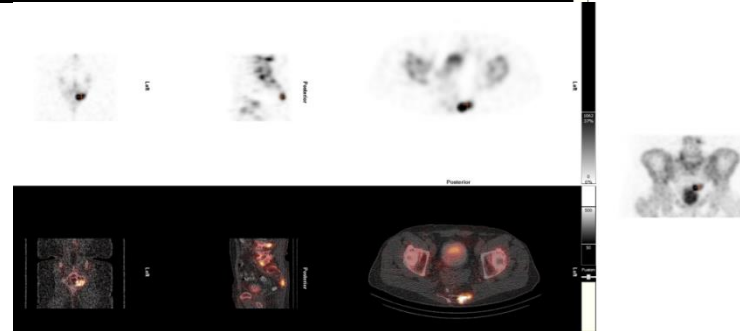


- Age 68 yrs., Post OP
- PSA increased
- Bone Scan, (745 MBq Tc-99m-HDP)
- SPECT/CT

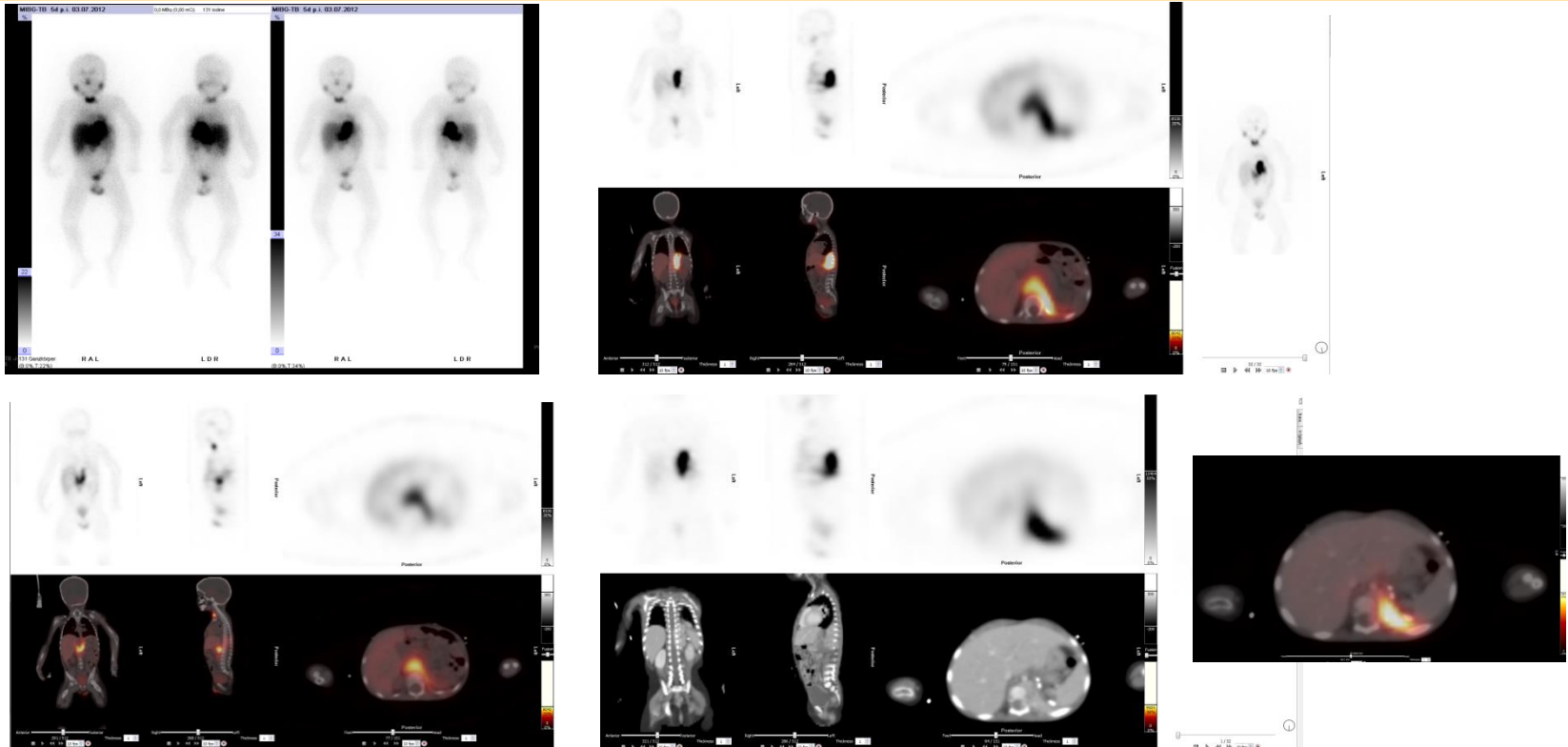
Staging II
Pedicle of vertebral arch



Staging III
Metastasis Os sacrum

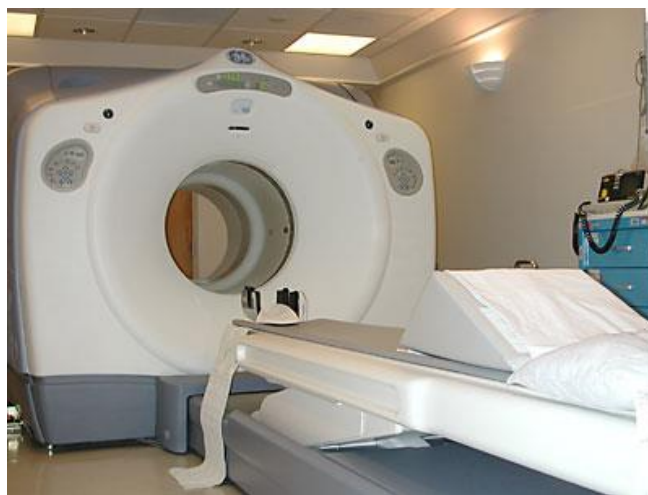
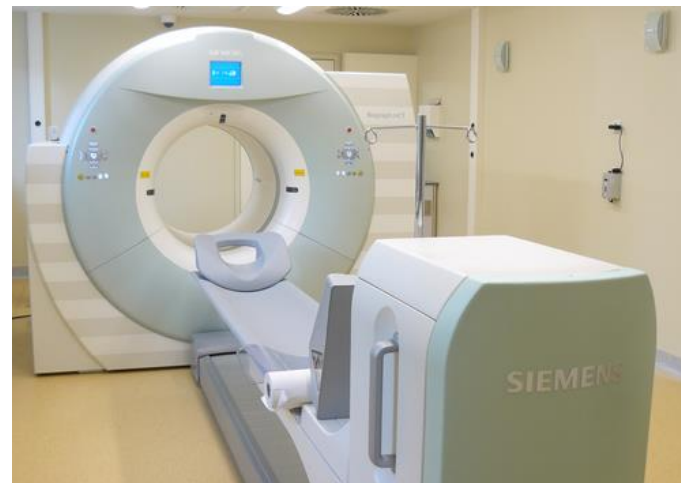
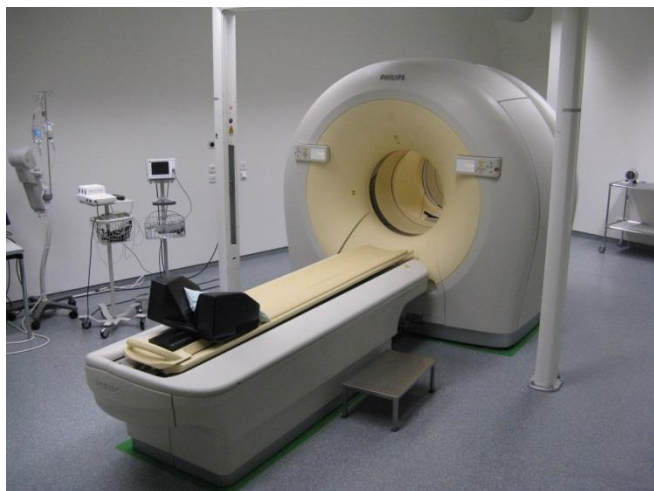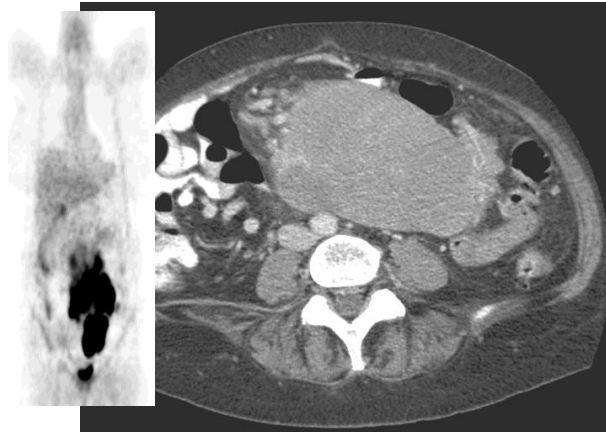
MIBG SPECT/CT



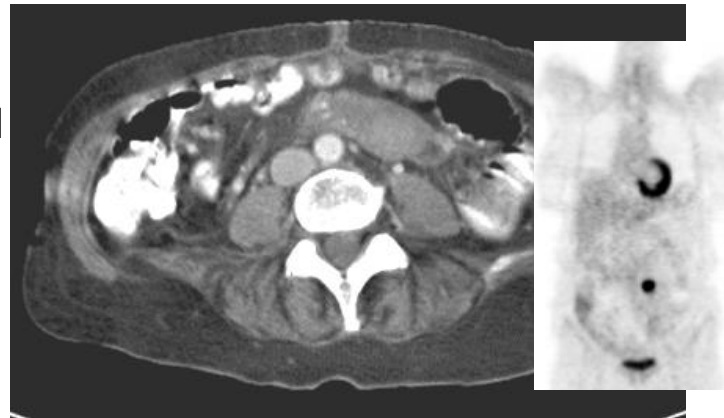
- 2 yrs., Neuroblastoma Stage IV, post therapy, Neuroblastoma recurrence with cerebral and abdominal metastases, Tumour progress under recurrence therapy
- Planar imaging and SPECT/CT with contrast agent 5 days post therapy

PET/CT

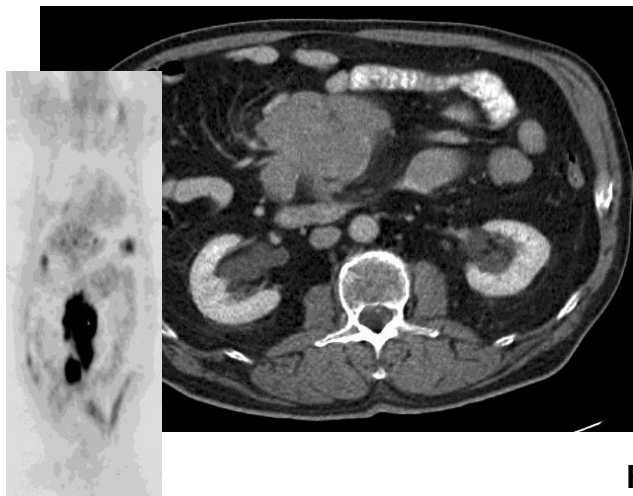




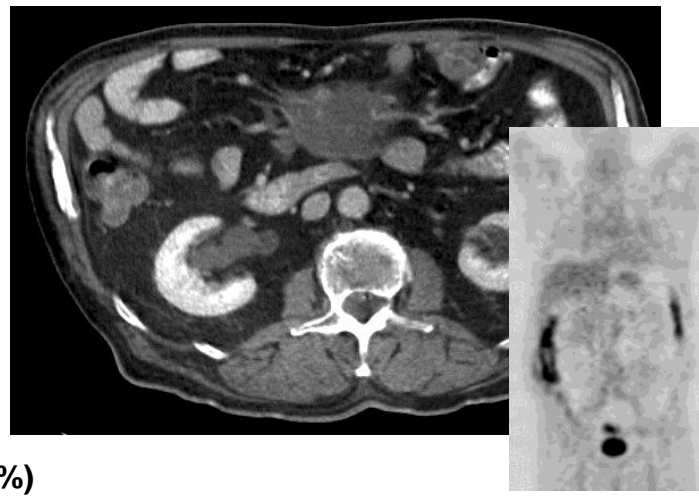
Patient 1



CRu (SPD – 84%)



Patient 2



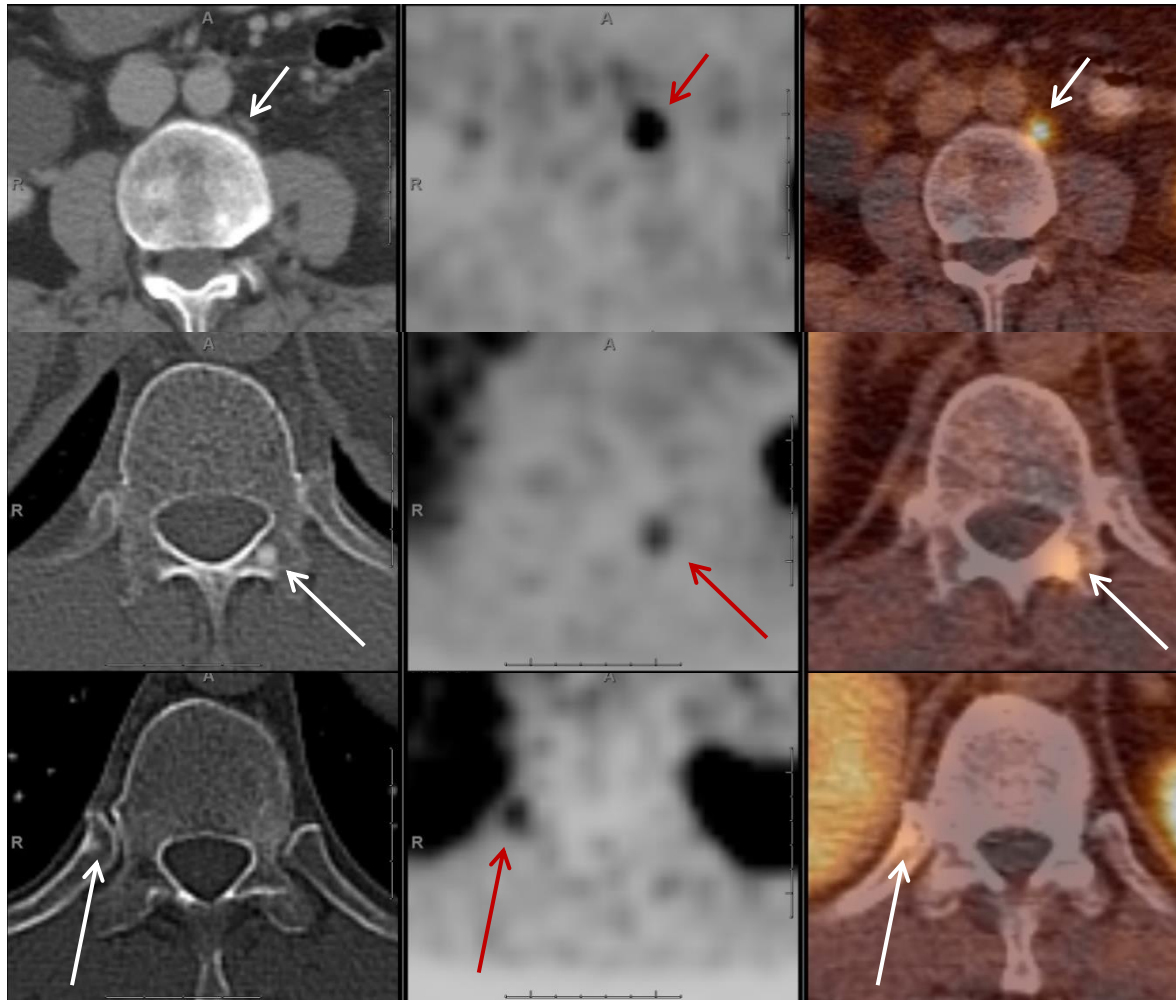
PR (SPD – 55%)

PSMA PET/CT

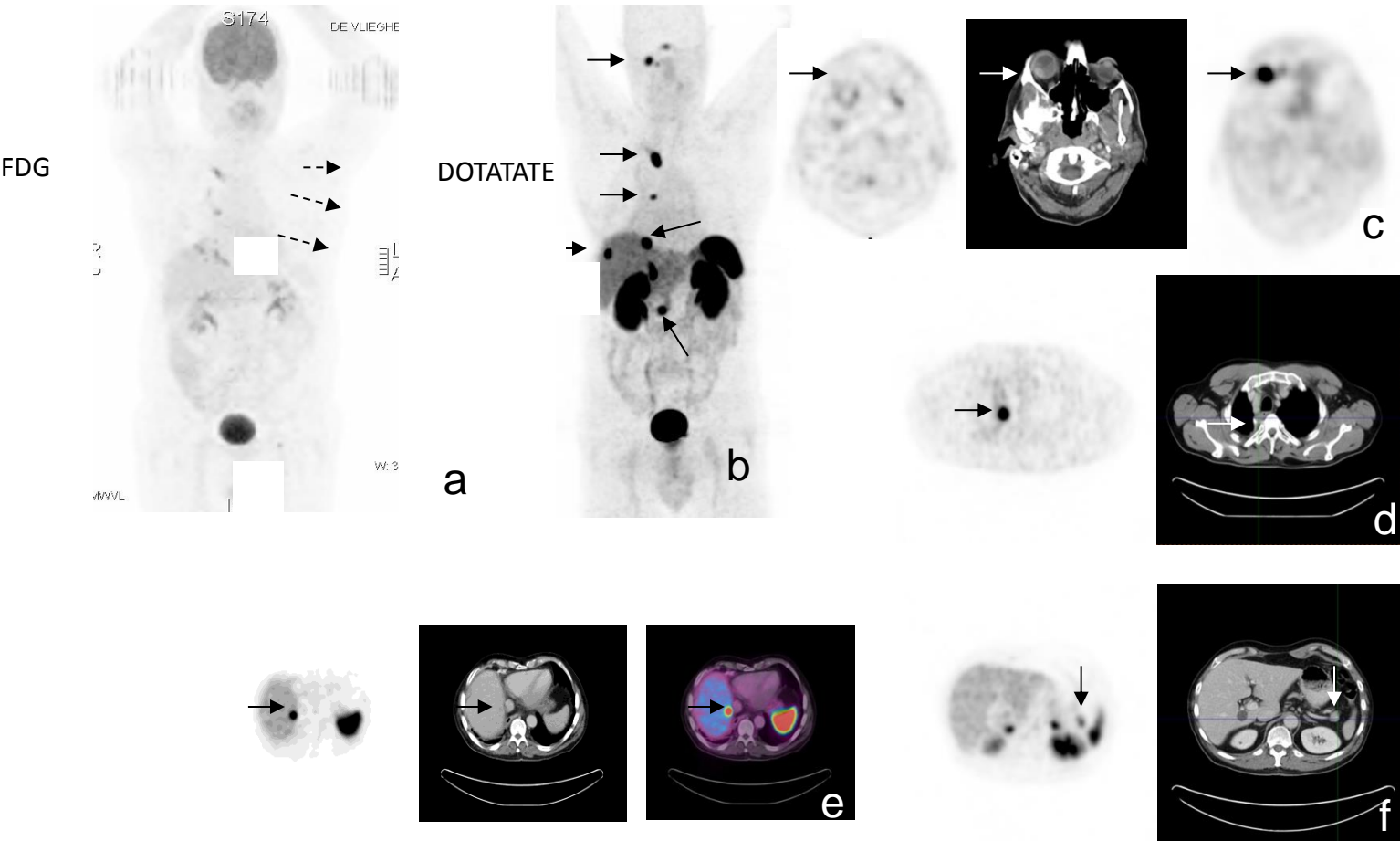
CT

PET

Fusion



Bronchial carcinoid with sudden onset of blurry vision



Small animal imaging

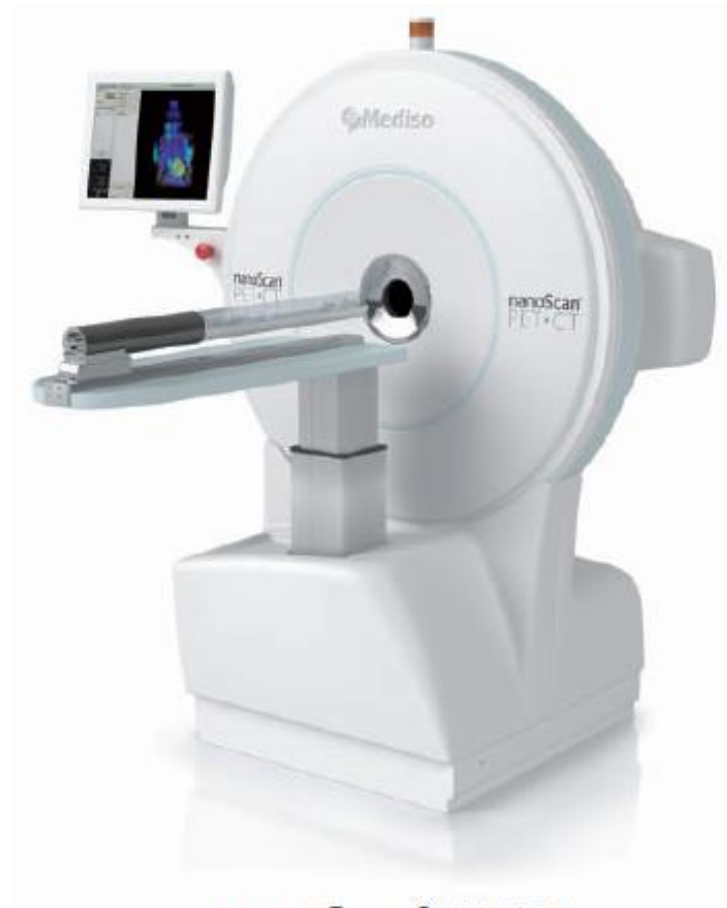- Important for development of new tracer
- Final preclinical step in the process from bench to bedside

- μ SPECT / CT
- μ PET / CT

Small Animal Imaging / Model Examples





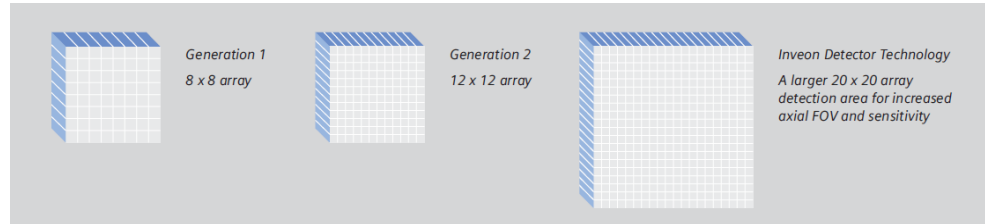
Small Animal -PET/CT



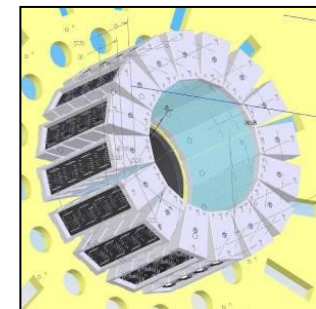
nanoScan® PET/CT

Micro PET: Dedicated Small Animal System

- Micro PET Siemens Inveon



Detector diameter: 16,1 cm
Transaxial FOV: 10,0 cm
Axial FOV: 12,7 cm
Crystal-detectors: LSO - 64 Blocks
25600 Sum of single crystals
High resolution: 1,4 mm FWHM
Absolut Sensitivity: 100,0 cps / 1kBq , 10 %



Micro PET: Dedicated Small Animal System


- Micro PET Siemens Inveon

Micro PET - measurement of the glucose metabolism with ^{18}F -FDG and of the skeleton with the bone affine radiopharmaceutical ^{18}F -NaF in a mouse.

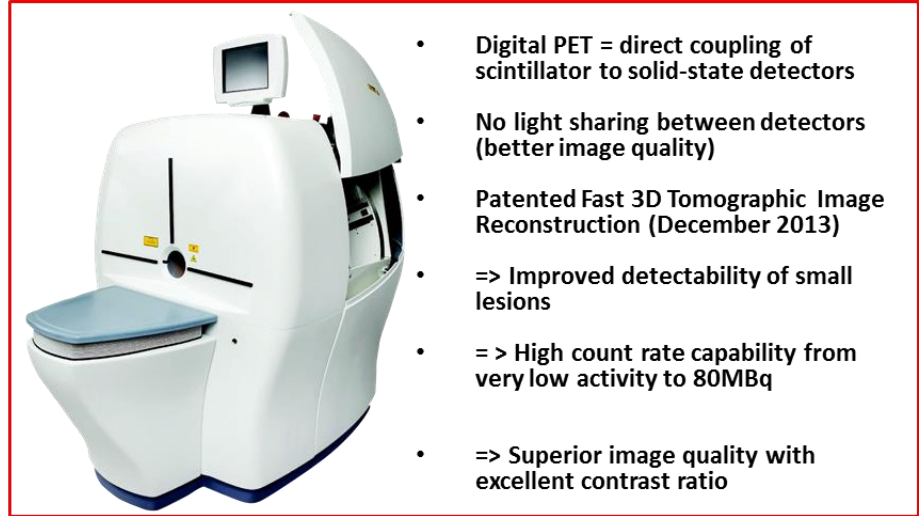


^{18}F -Sodium fluoride



^{18}F -Fluorodesoxyglucose



Digital PET Sub-System



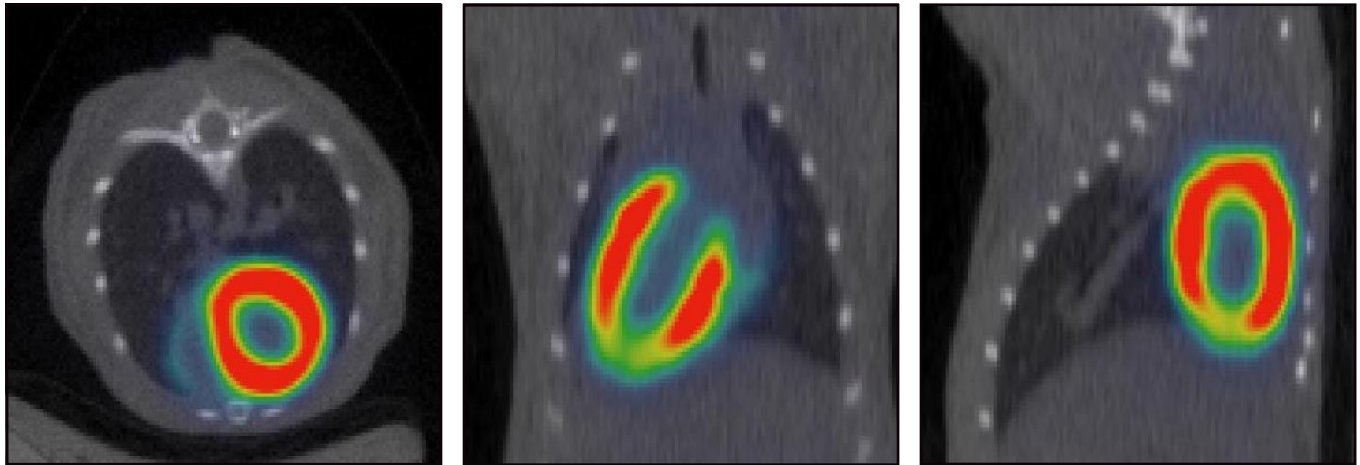
- ◆ Bore diameter: 15cm
- ◆ Transaxial FOV: User-selectable 46-100 mm
- ◆ Axial FOV: 30cm (continuous motion)
 - LabPET4
 - LabPET8
 - LabPET12

- Quad-APD detector modules coupled with LYSO/LGSO phaswich scintillators
- Individual readout, parallel signal processing
- Fully integrated with SPECT and CT;
- field- upgradable


TriFoil

PET/CT Cardiac Imaging - Mouse

PET/CT:
0.7mCi of
FDG, 20min.
Post injection,
5 min. scan

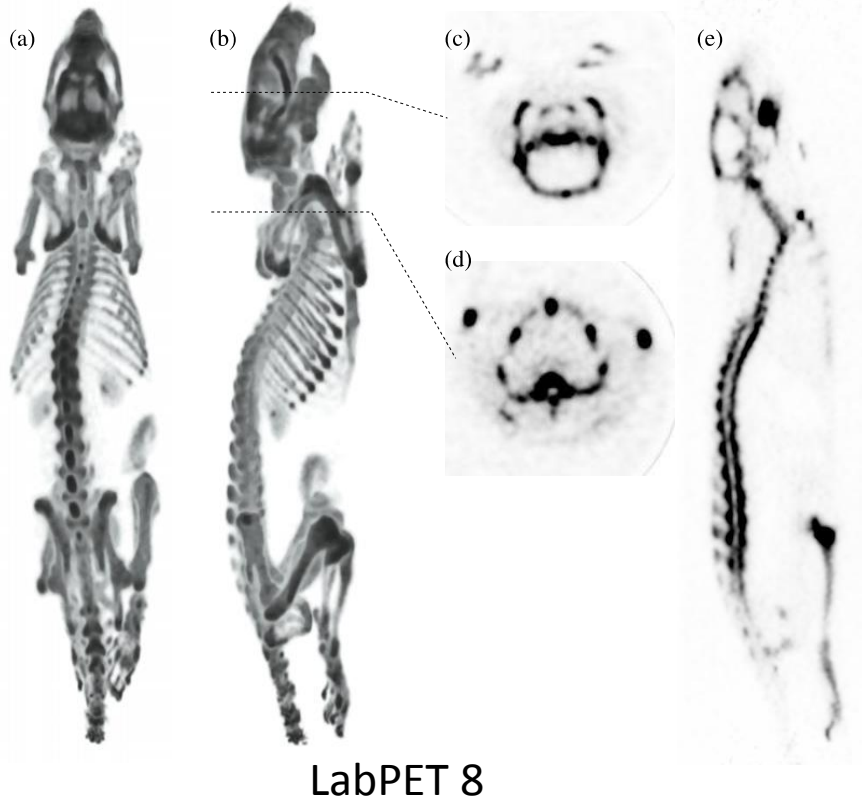


Detail of gated
cardiac images



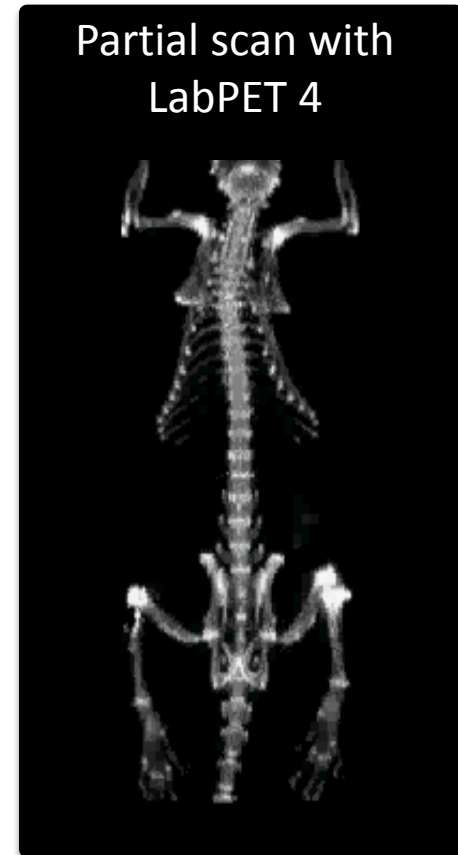
Courtesy of Dr. Ren-Shyan Liu, National Yangming University, Taipei, Taiwan

Excellent isotropical resolution: 185 g rat



LabPET 8

Figure 10. Volume-rendered images (a), (b) of a 185 g rat injected with 31 MBq of Na^{18}F and scanned 68 min post-injection on the LabPET8. Transaxial slices of the skull (c) and the ribcage (d) and a sagittal slice (e) are shown. The whole-body image was obtained by acquiring five overlapping decay-compensated scans with 3.78 cm steps for a total of 60 min. The image was obtained with a lower energy threshold of 350 keV and reconstructed using 80 3D MLEM iterations.

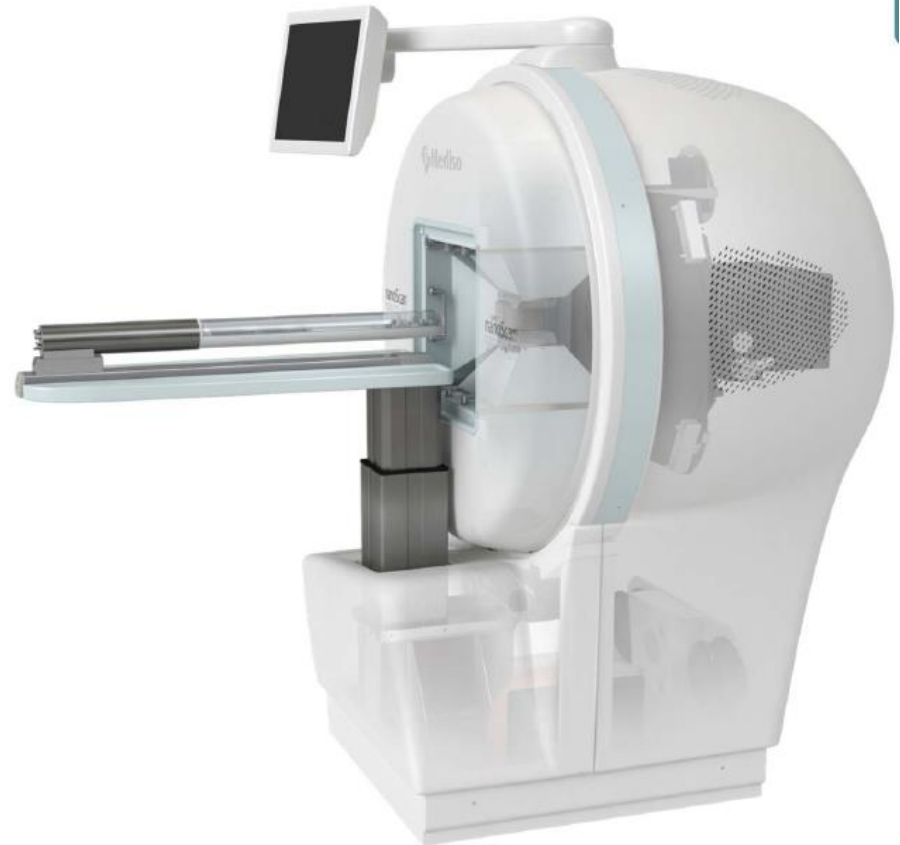

Reference: Imaging performance of LabPET APD-based digital PET scanners for pre-clinical research; M. Bergeron et al.; Universite de Sherbrooke, QC, Canada; Phys. Med. Biol. 59 (2014) 1–18

Small Animal Imaging / Model Examples



Small Animal -SPECT/CT

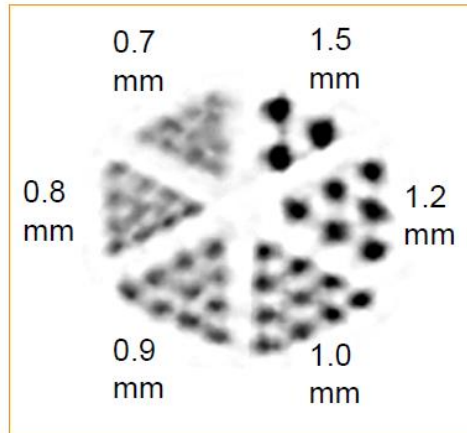


Small Animal -SPECT/CT


MMP - S P E C T

- Micro SPECT: Measurement of the bone skeleton with ^{99m}Tc -HDP


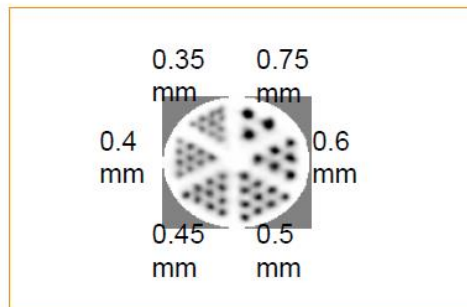
Rat collimator



Rat - ^{99m}Tc -HDP

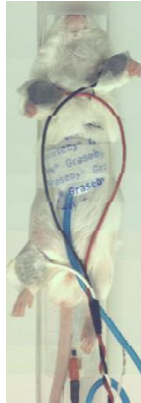


Mouse - ^{99m}Tc -HDP

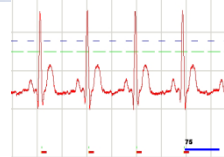


U-SPECT-II

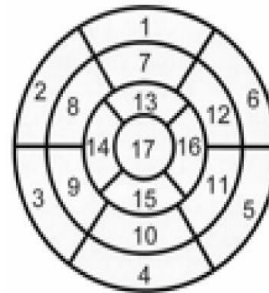
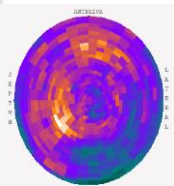
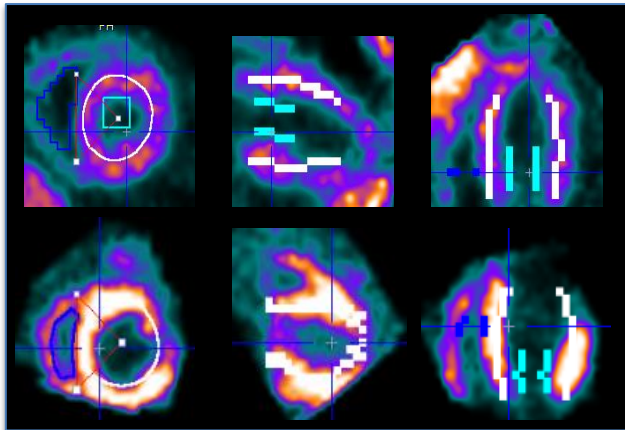
^{99m}Tc -MIBI




ECG gating



CARDIAC PMOD – 17 segment model

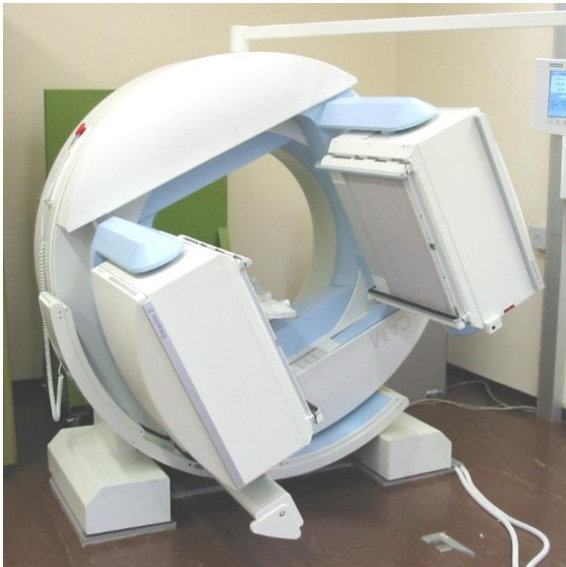

- | | | |
|------------------------|-----------------------|---------------------|
| 1. basal anterior | 7. mid-anterior | 13. apical anterior |
| 2. basal anteroseptal | 8. mid-anteroseptal | 14. apical septal |
| 3. basal inferoseptal | 9. mid-inferoseptal | 15. apical inferior |
| 4. basal inferior | 10. mid-inferior | 16. lateral |
| 5. basal inferolateral | 11. mid-inferolateral | 17. apex |
| 6. basal anterolateral | 12. mid-anterolateral | |

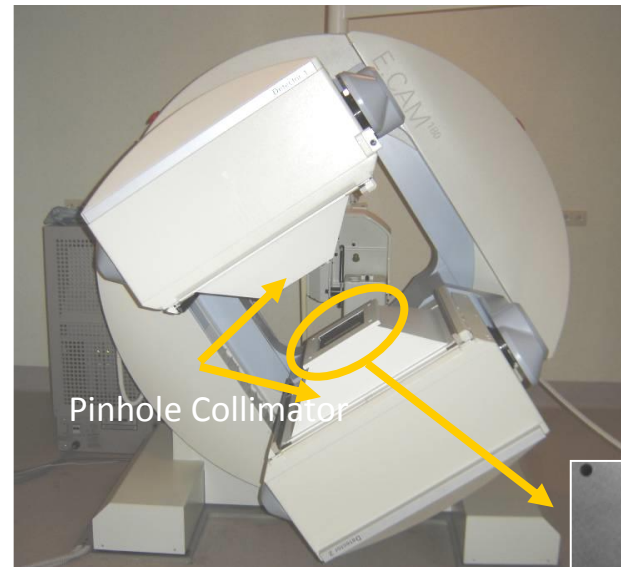



Multiplex Multi Pinhole (MMP) - S P E C T


- Micro SPECT: MMP-Technology with a clinically used SPECT gamma camera
 - Physical measuring principals
 - Characterisation and performance parameters



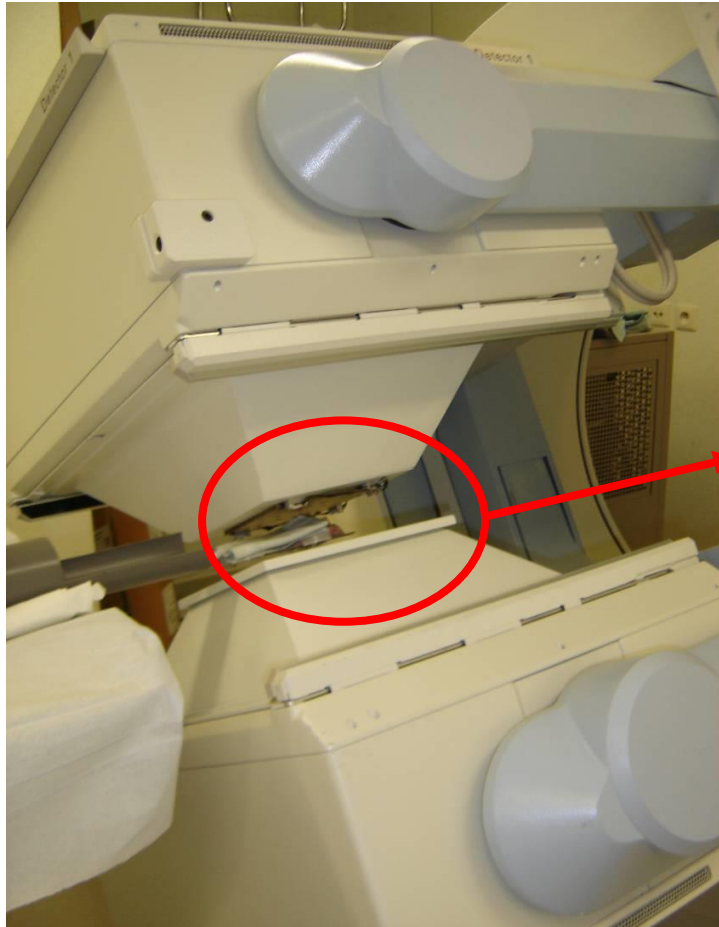Siemens SPECT E.cam gamma camera



7-Pinhole Aperture Plate



MMP - S P E C T

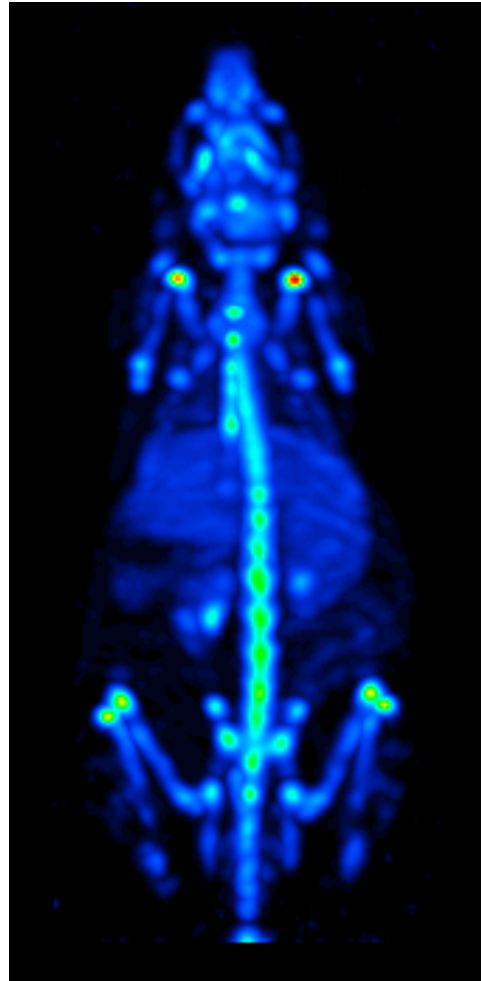


MMP - S P E C T

- Micro SPECT: Measurement with MMP-Technology by a clinically used SPECT gamma camera

- SPECT

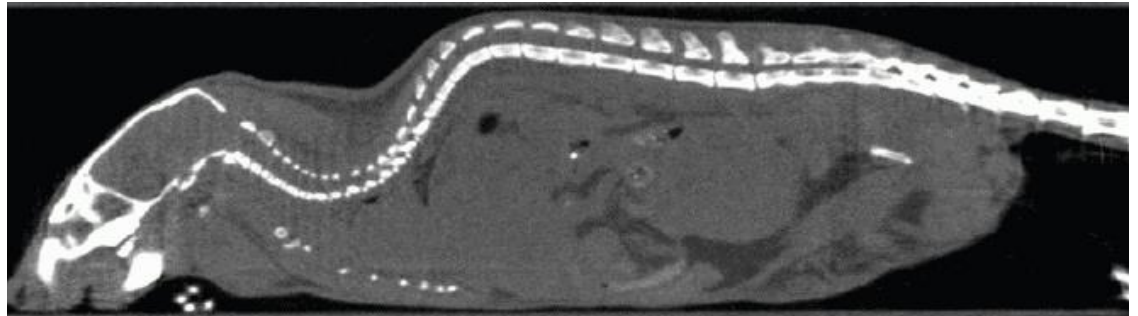
^{99m}Tc -HDP



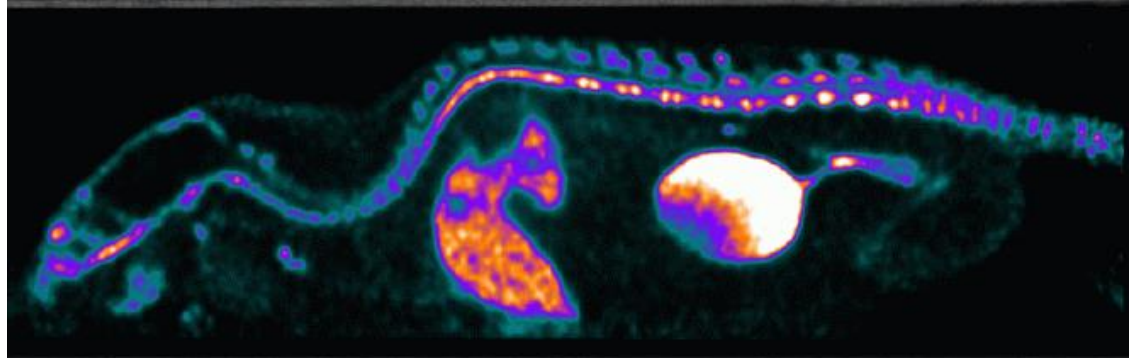
MMP - S P E C T

- **Micro SPECT:** Measurement of a mouse bone skeleton with ^{99m}Tc -HDP

CT

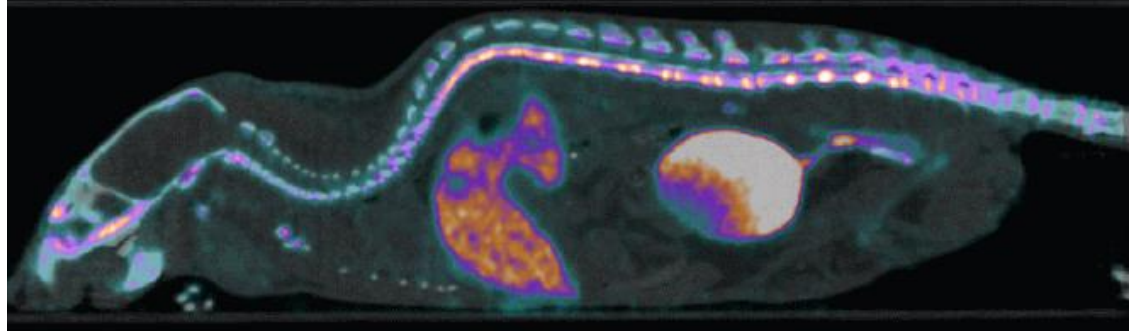


^{99m}Tc -Hydroxy-Diphosphonat



Fusion

CT - ^{99m}Tc -HDP SPECT



Biodistribution of ^{123}I -5-iodo-4'-thio-2'-deoxyuridine (^{123}I -ITdU) in WiDr xenografted mouse models

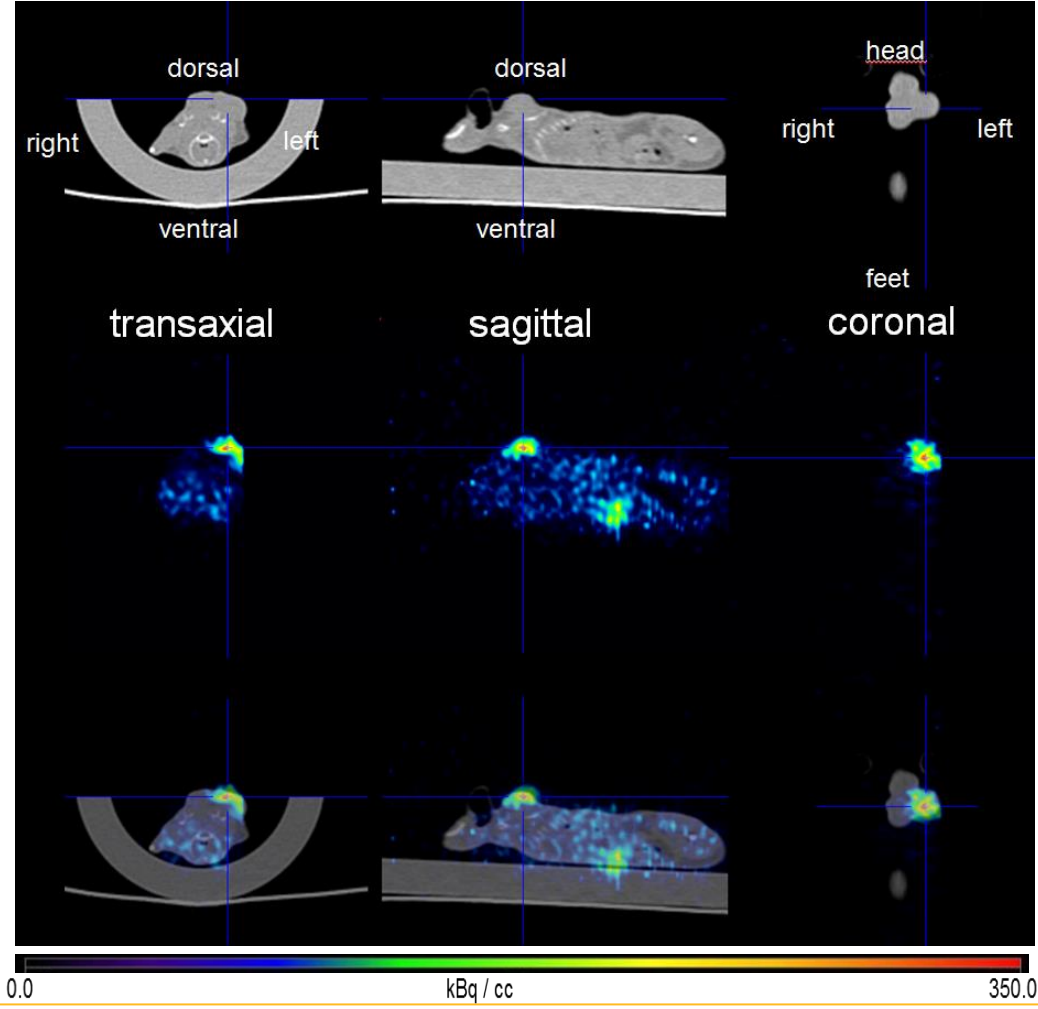
MMP μSPECT , 10.0 MBq 60 min p.i.

CT

μSPECT [^{123}I]-ITdU
FdUrd-Appl.

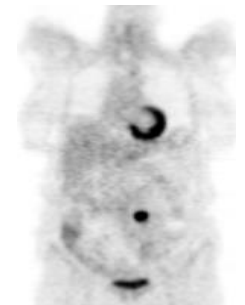
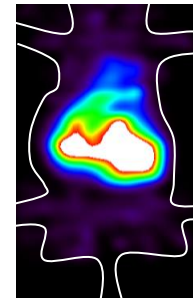
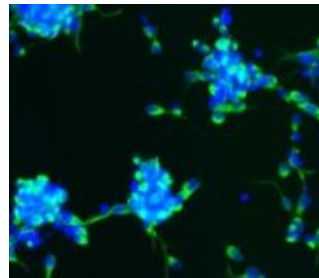
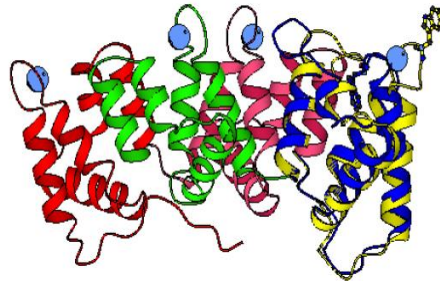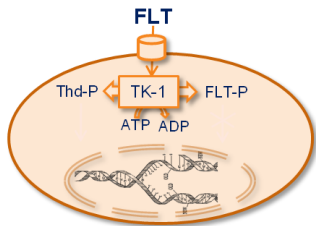
Fusion

μSPECT [^{123}I]-ITdU
+ CT



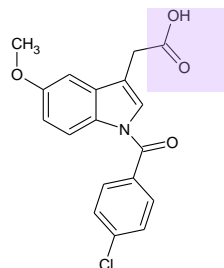
Examples for small animal imaging: biodistribution studies play a major role

- **New tracer development**
- **New pharmaca development**
- **Therapy studies**

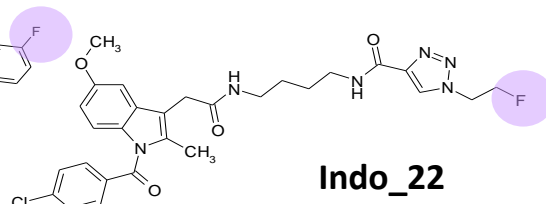
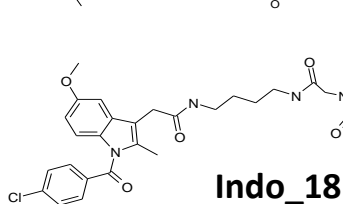
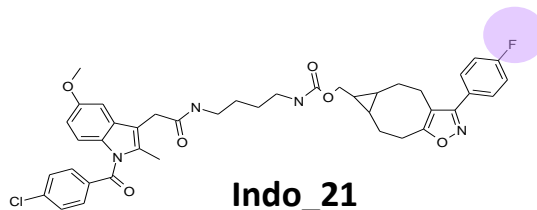
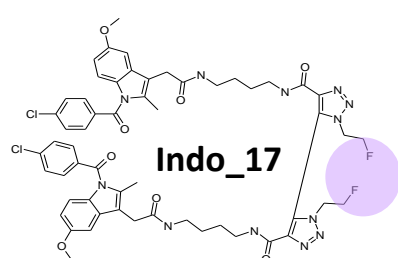
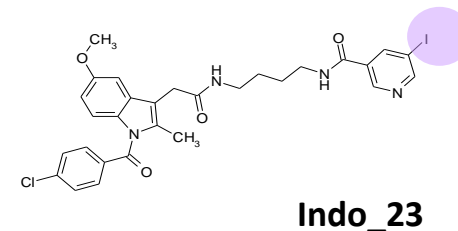
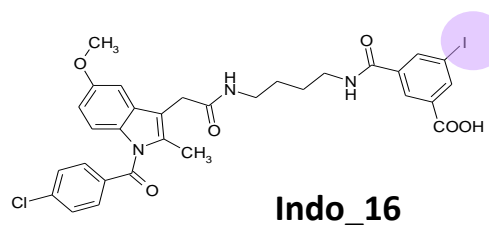
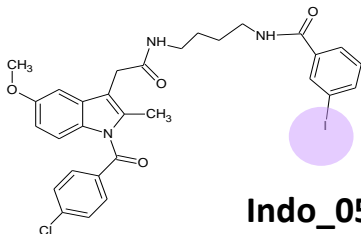


Indomethacin derivatives targeting COX2

Indomethacin as chemical lead



Derivatization at carboxylic acid \Rightarrow Indomethacin-Derivate with different Polarity and charge for labeling with radio iodine and radio fluor



Cite this: *Chem. Commun.*, 2012, 48, 7134–7136

www.rsc.org/chemcomm

COMMUNICATION

Beyond azide–alkyne click reaction: easy access to ^{18}F -labelled compounds *via* nitrile oxide cycloadditions†

Boris D. Zlatopolskiy,^{a,b} René Kandler,^b Diana Kobus,^b Felix M. Mottaghy^{a,c} and Bernd Neumaier^{a,b}

Applied Radiation and Isotopes 70 (2012) 184–192



Contents lists available at ScienceDirect

Applied Radiation and Isotopes

journal homepage: www.elsevier.com/locate/apradiso

C-(4-[^{18}F]fluorophenyl)-N-phenyl nitrene: A novel ^{18}F -labeled building block for metal free [3+2]cycloaddition

Boris D. Zlatopolskiy^{a,b}, René Kandler^b, Felix M. Mottaghy^{b,c}, Bernd Neumaier^{a,*}

^aMax Planck Institute for Neurological Research, Glienicker Straße 50, 50931 Cologne, Germany

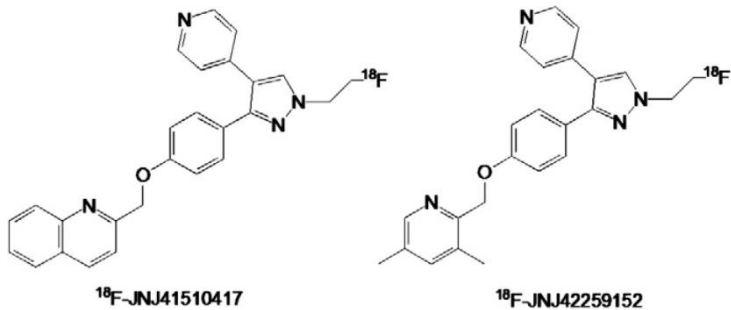
^bKlinik für Nuklearmedizin, Aachen University, RWTH, Pauwelsstr. 30, 52074 Aachen, Germany

^cDepartment of Nuclear Medicine, Maastricht University Medical Center, P. Debyeplein 25, 6229BX Maastricht, the Netherlands

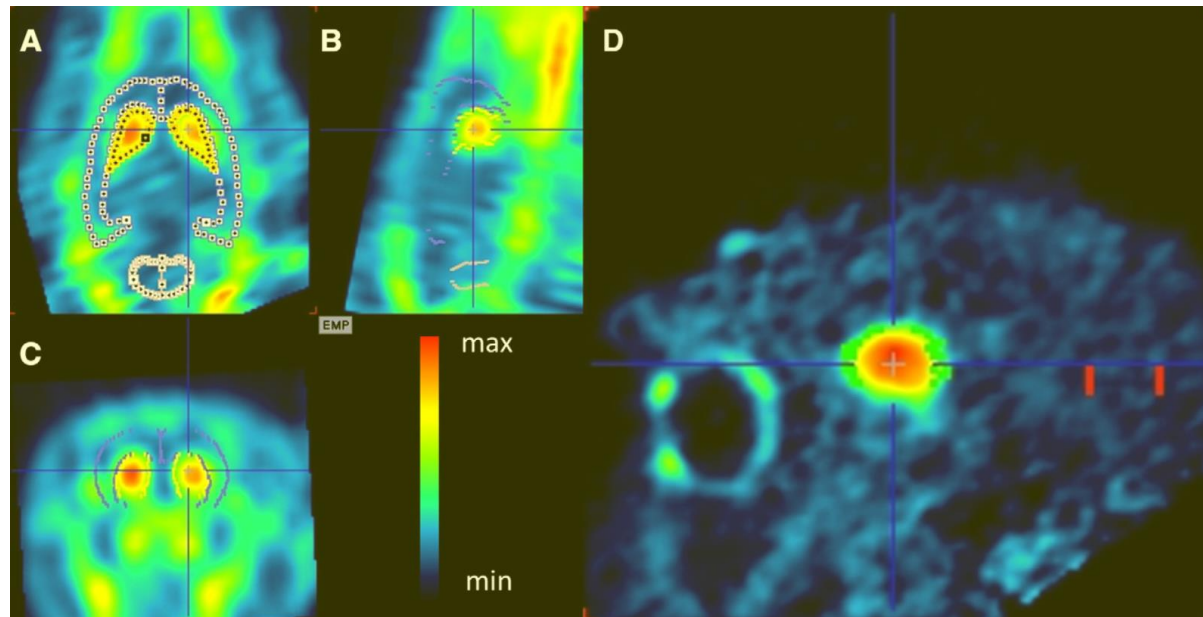
Confidential slides
will be presented



New pharmaca development

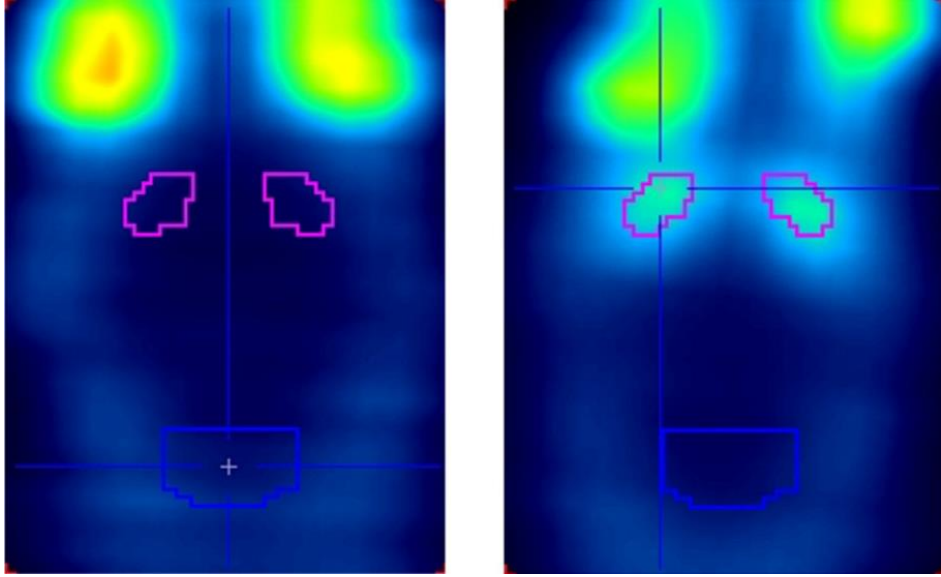
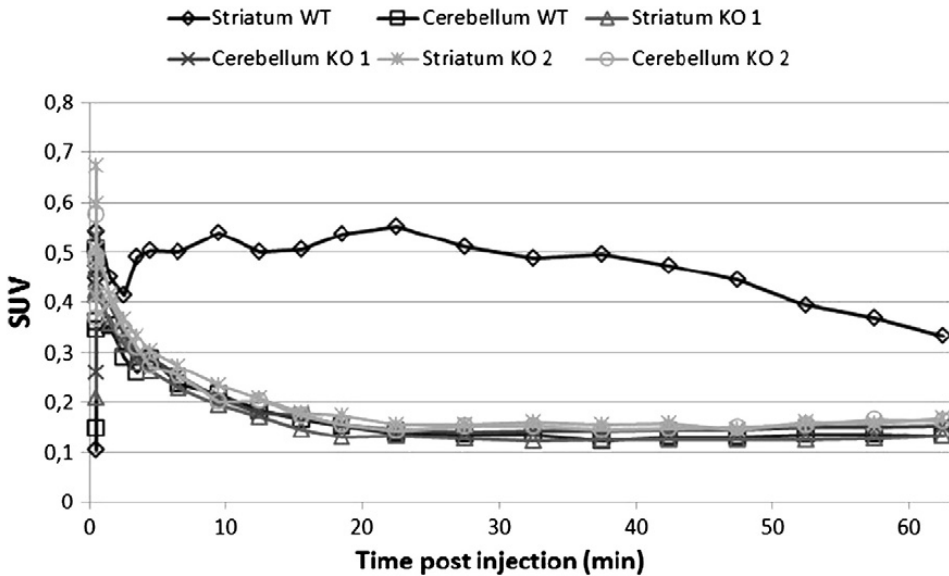


Phosphodiesterase-10A (PDE10A) is implicated in several neuropsychiatric disorders involving basal ganglia neurotransmission, such as schizophrenia, obsessive–compulsive disorder and Huntington's disease.



S. Celen et al. *NeuroImage* 82:13–22, 2013

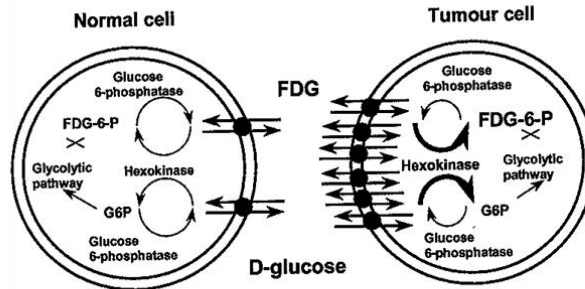
New pharmaca development



Small-animal PET transversal sections of KO (left image) and WT (right image) mouse brain injected with [18F]JNJ42259152 (summed images from 0 to 60 min post tracer injection). ROIs were drawn on the areas corresponding to striatum and cerebellum to obtain the TACs of [18F]JNJ42259152 in striatum and cerebellum of two PDE10A KO mice and one WT mouse (WT = wild type mouse, KO = PDE10A knock-out mouse).

Glucose metabolism: therapy response

^{18}F -FDG – PET

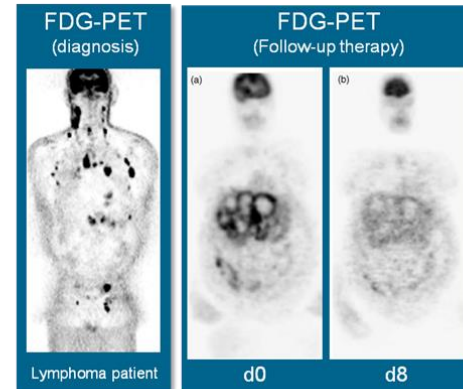
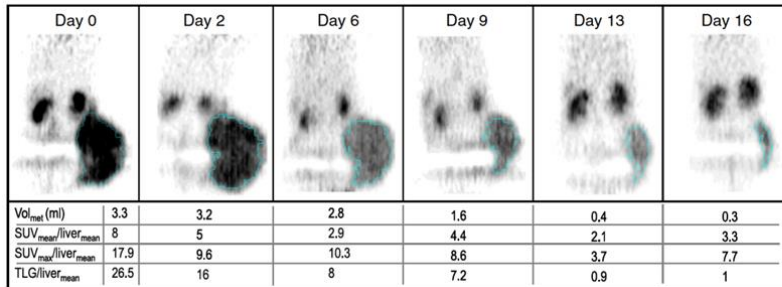


Eur J Nucl Med Mol Imaging (2010) 37:1688–1695
DOI 10.1007/s00259-010-1479-0

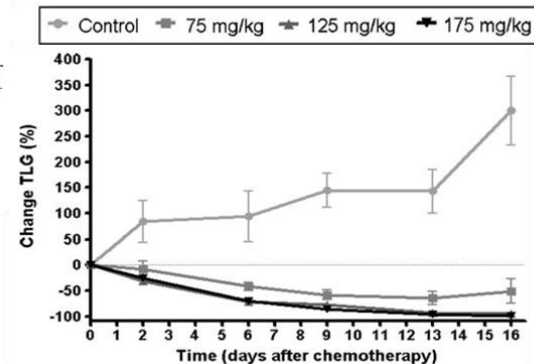
ORIGINAL ARTICLE

Dose-response relationship in cyclophosphamide-treated B-cell lymphoma xenografts monitored with [^{18}F]FDG PET

Lieslot Brepoels · Marijke De Saint-Hubert ·
Sigrid Stroobants · Gregor Verhoef · Jan Balzarini ·
Luc Mortelmans · Felix M. Mottaghy



Stroobants et al., E J Cancer 2003



→ [^{18}F]FDG –Uptake represents dose-effect-dependency of Cyclophosphamid

Proliferation: Therapy Response

¹⁸F-FLT – PET

Am J Nucl Med Mol Imaging 2012;2(1):110-121
www.ajnmj.us /ISSN:2160-8407/ajnmj1111001

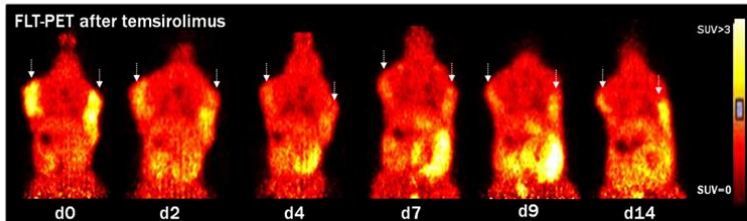
Original Article

Molecular imaging of therapy response with ¹⁸F-FLT and ¹⁸F-FDG following cyclophosphamide and mTOR inhibition

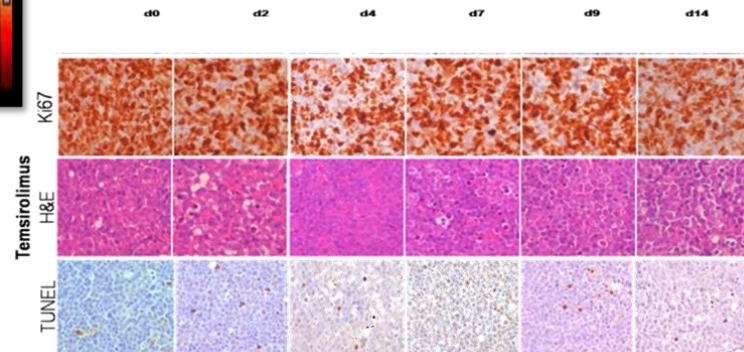
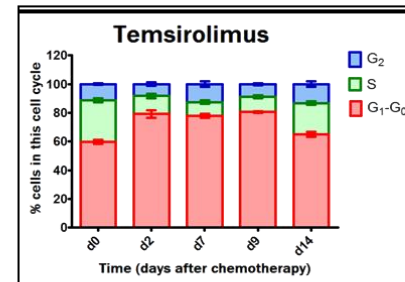
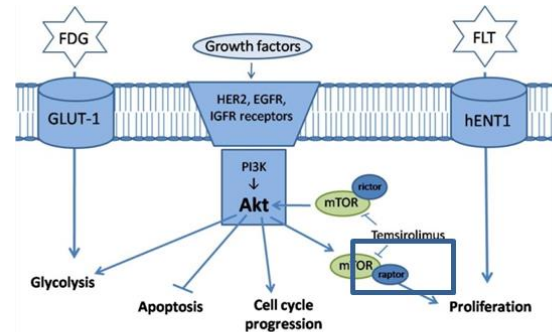
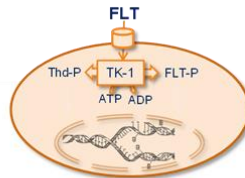
Marijke De Saint-Hubert¹, Lieselot Brepoels², Ellen Devos², Peter Vermaelen², Tjibbe De Groot³, Thomas Tousseyn⁴, Luc Mortelmans², Felix M Mottaghy^{1,2,5}

¹Department of Nuclear Medicine, Maastricht University Medical Centre, Maastricht, The Netherlands; ²Department of Nuclear Medicine, Katholieke Universiteit Leuven, Leuven, Belgium; ³Laboratory for Radiopharmacy, Katholieke Universiteit Leuven, Leuven, Belgium; ⁴Morphology and Molecular Pathology, Katholieke Universiteit Leuven, Leuven, Belgium; ⁵Department of Nuclear Medicine, University Hospital RWTH Aachen, Germany

Received November 5, 2011; accepted November 18, 2011; Epub December 15, 2011; Published January 1, 2012



- FLT-PET represents reduced proliferation after temsirolimus.
- Correlates with the end of mitosis (Increase of G₀/G₁ in Facs) and ki67- staining



Take home

- SPECT and PET
 - provide a broad spectrum of diagnostic approaches
 - help to understand biological processes
 - are an important link in the „bench to bedside“ concept of probe development
- Molecular Imaging
 - is important for non-invasive monitoring of disease
 - supports development of new theranostic concepts

